



## **Frequency of gall bladder diseases in 200 cholecystectomies lesions.**

**Jha RK (MBBS, MD) \* Yadav DP (PhD)**

Professor & HOD Department of Pathology, B & C Medical College, Teaching Hospital and Research

**\*Dr. Raj Kumar Jha**

Professor & Head, Department of Pathology, B & C Medical College, Teaching Hospital and Research,  
Birtamode Jhapa, Nepal Mob: +977- 9744010250

E- mail: [jharajkumar676@gmail.com](mailto:jharajkumar676@gmail.com), [ddineshh2004@gmail.com](mailto:ddineshh2004@gmail.com)

### **Abstract**

The exact picture of gall bladder diseases in cholecystectomies is not known. In this study, the purpose is to report the morphologies and frequency of gall bladder diseases in 200 cholecystectomies lesions in the last two years in our pathology laboratory. The age of patients ranged from 22 year to 81 year. Male to female ratio was 1:4. Out of 200 cholecystectomies lesions 190 cases (95%) had gall stones. Out of these three (1.5%) were acute cholecystitis, 187(93.5%) were chronic cholecystitis four (4 cases) – (2%) were adenocarcinoma and 6 ( 3%) normal gall bladder. The frequency of histological lesions were: acute gangrenous inflammation (2 cases %), Rokitansky Aschoff sinuses (RAS) (140 cases 70%), microliths (40 cases 20%), Adenomyomatous changes (8 cases 4%), focal abscess formations ( 4 cases 2%).

**Keywords:** gall bladder diseases, cholecystectomies, Male to female ratio.

### **Introduction**

Various lesions occur in the gall bladder. The most common is gall stones. Gall bladder with gall stones frequently show chronic cholecystitis. Chronic cholecystitis mostly shows fibrosis of the wall, muscular hypertrophy and lymphocytic infiltration. Carcinomas also occur in the gall bladder. However, frequency of these lesions is not clear. The purpose of the present study is to report the morphologies and frequency of gall bladder diseases and lesions of 200 cholecystectomies in the last 2 year in our pathology laboratory.

### **Materials and Methods**

The author retrospectively received the HF preparation of cholecystectomies in the last two years in pathology laboratory. Cutting of the gall bladder was performed by the author. A few specimens were cut from the cystic duct to gall bladder fundus in each case. When other lesions were found, they were prepared separately. The average number of preparations per case was 3-4. The sampling did not influence the pathological observations. Clinical record were also reviewed.

## Results

A total of 200 cholecystectomies were found. The age of patients ranged from 22 years to 81 years. Male to female ratio 1:4 .of these, 190 cases (95%) had gall stones. The type of gall stones

were not described in 84 clinical records. The number and percentage of gall stones were cholesterol stones 19% (22 cases) Bilirubin stones 47% (55 cases) and mixed stones 33% (38 cases) and calcium carbonate stone in 1% (1 cases).

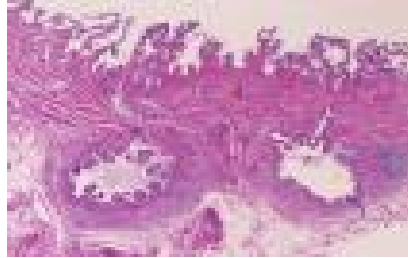

Fig: 1 Histopathology of Rokitansky Aschoff sinuses. Two Rokitansky-Achoff sinuses are seen in the subserosa. 40x

Detection of gall stones and gall bladder diseases was made mostly by abdominal echo and few cases underment endoscopic retro grade cholangiography. The reason for cholecystectomies was acute cholecystitis in 3

cases, gall stones with chronic cholecystitis in 179 cases, gall bladder polyps in 9 cases, Suspected gall bladder carcinoma in 5 cases and cholecystectomy of the normal gall bladder during gastric carcinoma in 4 cases.

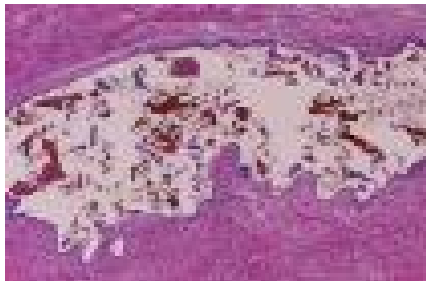

Fig: 2 Histopathology of Microliths or inspissated bile within a Rokitansky-Aschoff sinus. They are pigment microliths. HE, x100.

Acute cholecystitis was found in 3(1.5%) cases. They were microscopically characterized by heavy neutrophilic infiltration with frequent ulcer

formatious, gangrenous changes and abscess formatious.

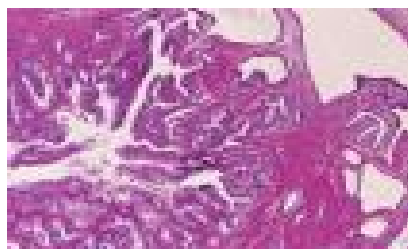

Fig: 3 Histopathology of Adenomyomatous changes. Proliferation of cystic epithelium and hypertrophy of smooth muscles are evident. HE, x 40.

Rokitansky- Aschoff sinuses (RAS) were recognized in 130 cases (65%) with chronic cholecystitis. They were characterized by a cystic spaces lined by a layer of columnar epithelium in the fibromuscular or serosal layers. The presence

of microliths or inspissated bile within R- A sinuses was recognized in 40 cases (31%) of 130 cases. Adenomatous changes were present in 6 cases (3%). They were characterized by many RA sinuses and muscular hypertrophy.




Fig: 4 Histopathology of Cholesterol polyp. A polyp containing foamy macrophages is seen. HE, x100.

Cholesterosis was identified in 22 cases (11%) and it was characterized by infiltration of foamy macrophages in the mucosa. All cases of cholesterosis were associated with chronic cholecystitis. Cholesterol polyp was seen in 12

cases (6%). It is characterized by a small polyp containing foamy macrophages. It was frequently multiple and grossly characterized small yellow polyp.

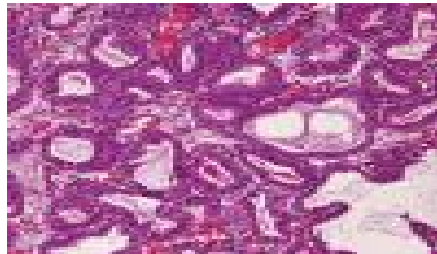


Fig: 5 Histopathology of Tubular adenoma of intestinal type. A glandular adenomatous proliferation is recognized. HE, x 100.

Tubular adenoma was demonstrated in 3 cases (1.5%). All of the adenoma was of intestinal type in this series. It is characterized by adenomatous proliferation of intestinal type epithelium. Invasive adenocarcinoma was recognized in 4 cases (2%). Of these, 2 were tubular, one

papillary and one was mucinous adenocarcinoma. The adenocarcinoma arose from RAS epithelium. Cystadenocarcinoma was noted in 1 case. This was characterized by an invasive adenocarcinoma with cystic formations.




Fig: 6 Histopathology of Gall bladder adenocarcinoma. Tubular adenocarcinoma with invasion is noted. HE, x40.

In the present series, there was no cases of heterotopic tissue, intestinal metaplasia, biliary intraepithelial neoplasm and other malignancies.

## Discussion and Conclusion

The histopathological features and incidence of (4) gall bladder lesions varies depending on races, countries and institutes. It is well known that gall bladder diseases affect more frequently women than men. The gall bladder diseases most frequently occurs in middle age population. The present series are compatible with these other data.

The frequency and pathologic features of acute cholecystitis is unclear. In the present series, acute cholecystitis was found in 1.5% cases. They were characterized by phlegmonous neutrophilic infiltration with frequent ulcer formations, gangrenous changes and abscess formations.

The frequency of RAS is not known. RAS is though to be epithelial herniation due to increased gall bladder inner pressure. RAS is rarely seen in normal gall bladders. RAS is among the lesions of chronic cholecystitis in the present series. RAS were recognized in 65%. The frequency of microliths or inspissated bile within RAS was unknown. In the present series, they were recognized in 31%. The frequency of adenomatous changes was unclear. In the present series, they were present in 3%. The incidence of cholesterosis in the present series was identified in 11% but it may be different in other series due to the difference in fat ingestion or accuracy of pathologic observation. The frequency of gall bladder polyps in the present study was 6%. It was frequently multiple & grossly characterized by small yellow polyp. Gall bladder tubular adenomas were classified into gastric type and intestinal type. The frequency of tubular adenoma in the gall bladder was unknown. The present study revealed that the incidence of tubular adenoma is 1.5%. In the present series, all of the adenoma was of intestinal type. In the present series, invasive adenocarcinoma was recognized in 4 cases (2%). Of these two were tubular adenocarcinomas. One was papillary adenocarcinoma and one was mucinous

adenocarcinoma. The adenocarcinoma arose from RAS epithelium. Adenocarcinoma arising within RAS is extremely rare, only a few cases are reported in the literature (3,12). Cystadenocarcinoma was noted in 1 case. This is also an extremely rare case to the author's knowledge. Only 5 cases are recorded in the English literature (4, 13, 15). This was characterized by an invasive adenocarcinoma with cystic formation. It is well known that hepatobiliary cystadenoma and cystadenocarcinoma is predominantly seen in middle-aged female and frequently have ovarian stroma like mesenchymal stroma (13, 16, 17). No mesenchymal stroma was present in the present case. Of these 5 carcinomas, 3 were incidental findings in pathologic examination. In the present series, there were no cases of heterotopic tissues, intraepithelial neoplasms, other malignancies. The present data may provide base knowledge of the gall bladder pathologies.

## References

1. Albores-Saavedra J, Menck HR, Scoazec JC, Soehendra N, Wittekind C, Sriram PV J, Spira B. Carcinoma of the gall bladder and extrahepatic bile ducts. In: Mamilton SR, Aaltonen LA, editors. WHO Classification of tumours. Pathology and genetics of tumours of the digestive system. Lyon: IARC Press; 2000. pp. 203–214.
2. Rosai J. Rosai and Ackerman's Surgical Pathology. Ninth edition. Mosby; 2000. Gall bladder and extrahepatic bile ducts; pp. 1035–1060.
3. Terada T. Gall bladder adenocarcinoma arising in Rokitansky-Aschoff sinuses. *Pathol Int.* 2008;58:806–809.
4. Terada T, Takeuchi T, Taniguchi M. Hepatobiliary cystadenocarcinoma with cystadenoma elements of the gall bladder in an old man. *Pathol Int.* 2003;53:790–795.
5. Zen Y, Adsay NV, Bardadin K, Colombari R, Ferrell L, Haga H, Hong SM, Hytiroglou P, Klöppel G, Lauwers GY, van Leeuwen DJ, Notohara K, Oshima K, Quaglia A, Sasaki M, Sessa F, Suriawinata A, Tsui W, Atomi Y, Nakanuma Y. Biliary intraepithelial neoplasia: an international interobserver agreement study

- and proposal for diagnostic criteria. *Mod Pathol.* 2007;20:701–709.
6. Tyagi SP, Tyagi N, Maheshwari Y, Ashraf SM, Sahoo P. Morphologic changes in diseased gall bladder: a study of 415 cholecystectomies at Aligarh. *J Indian Med Assoc.* 1992;90:278–181.
  7. Albores-Saavedra J, Hensen DE. Pyloric gland metaplasia with perineural invasion of the gall bladder: A lesion that can be confused with adenocarcinoma. *Cancer.* 1999;86:2625–2631.
  8. Albores-Saavedra J, Keenportz B, Bejarano PA, Alexander AA, Hensen DE. Adenomyomatous hyperplasia of the gall bladder with perineural invasion: revisited. *Am J Surg Pathol.* 2007;31:1598–1604
  9. Dixit VK, Prakash A, Gupta A, Pandey M, Gautam A, Kumar M, Shukla VK. Xanthogranulomatous cholecystitis. *Dig Dis Sci.* 1998; 43:940–942.
  10. Jorgensen T, Jensen KH. Polyps in the gall bladder: a prevalence study. *Scand J Gastroenterol.* 1990; 25:181–186.
  11. Myers RP, Schffer EA, Beck PL. Gall bladder polyps: epidemiology, natural history and management. *Can J Gastroenterol.* 2002; 16:187–194.
  12. Kawarada Y, Sanda M, Mizumoto R, Yatani R. Early carcinoma of the gall bladder, non-invasive carcinoma originating in the Rokitansky-Aschff sinus: a case report. *Am J Gastroenterol.* 1986;81:61–66
  13. Devaney K, Goodman ZD, Ishak KG. Hepatobiliary cystadenoma and cystadenocarcinoma: a light microscopic and immunohistochemical study of 70 patients. *Am J Surg Pathol.* 1994;18:1078–1091
  14. Waldmann J, Zielke A, Moll R, Schweinsberg TS, Rothmund M, Langer P. Cystadenocarcinoma of the gall bladder. *J Hepatobiliary Pancreat Surg.* 2006; 13:594–599.
  15. Sistla SC, Sanker G, Basu D, Venkatesan B. Biliary cystadenocarcinoma of the gall bladder: a case report. *J Med Case Rep.* 2009 Oct 15; 3:75.
  16. Terada T, Kitamura Y, Ohta T, Nakanuma Y. Endocrine cells in hepatobiliary cystadenomas and cystadenocarcinomas. *Virchows Archiv.* 1997; 430:37–40.
  17. Terada T, Nakanuma Y, Ohta T, Nagakawa T, Motoo Y, Harada A, Hamato N, Inaba T. Mucin-histochemical and immunohistochemical profiles of epithelial cells of several types of hepatic cysts. *Virchows Arch A Pathol Anat Histopathol.* 1991; 419:499–504.

<b>Access this Article in Online</b>	
	Website: <a href="http://www.ijcrims.com">www.ijcrims.com</a>
	Subject: <a href="#">Pathology</a>
<b>Quick Response Code</b>	

**How to cite this article:**

Jha RK , Yadav DP. (2017). Frequency of gall bladder diseases in 200 cholecystectomies lesions.. *Int. J. Curr. Res. Med. Sci.* 3(12): 39-43.

DOI: <http://dx.doi.org/10.22192/ijcrms.2017.03.12.006>